

Case Report

Agensis of Vermiform Appendix – A cadaveric study

Dr. Manish Arora

Faculty of Homoeopathic Science, Jayoti Vidyapeeth Women's University, Jaipur (Raj)

Corresponding author: Dr. Manish Arora

Abstract

The vermiform appendix in human is a vestigial organ. It may be absent in some cases in India. It is also known as “abdominal tonsil” because it contains lymphatic nodules. When it gets inflamed, can create trouble. So if no appendix is found in a case, we can say that the person escapes the ill-effects of the organ. We didn't found any appendix in our routine dissection classes.

Keywords- Vermiform appendix, inflamed, cadaver, dissection, abdominal tonsil.

Introduction

The vermiform appendix is a worm like diverticulum arising from the posteromedial wall of the caecum, about 2 cm below the ileocaecal orifice. Its length varies from 2 to 20 cm with an average of 9 cm. It is shorter in adults than in children. The diameter is about 5 mm. Lumen may obliterated after mid adult life.

Congenital absence of vermiform appendix is very rare in human beings. This has been reported in 0.0009% or 1 in 1,00,000 cases. According to the knowledge of comparative anatomy, there are many organs like ear pinna, plantaris muscle in leg, wisdom teeth, tail bone, semilunar fold of corner of the eye in our body can be categorised as vestigial structures. The vermiform appendix is the most common and the most disputed vestigial organ in our body. It is a topic of debate in current times that whether the gut-associated lymphoid tissue (GALT) in the human appendix performs any specialized function other than the function performed by the much larger lymphoid tissue already distributed throughout the gut. The GALT is distributed in the form of Peyer's patches in small intestine and in large intestine. In the literature of comparative vertebrate anatomy, it has been well written that the human appendix and the end of the mammalian caecum are homologous.

It has been proved that the human vermiform appendix is a vestigial organ and its removal after infancy does not cause any harm. Also, if it is absent since birth, a person can lead a normal life. But if it get inflamed it can lead to appendicitis. It can lead to a worst condition when an inflamed appendix gets bursts, which is a life threatening condition. Acute appendicitis is more common in young age. Anatomically, appendix presents a dead-end pocket, which opens in the caecum, through appendicular orifice. This can be blocked by faecal matter and can lead to appendicitis. Also, in 65% cases, the lymphoid hyperplasia leads to obstruction of the lumen causing acute appendicitis. Thus, we can say that if the lumen of appendix would be wider, then the incidence of appendicitis be reduced.

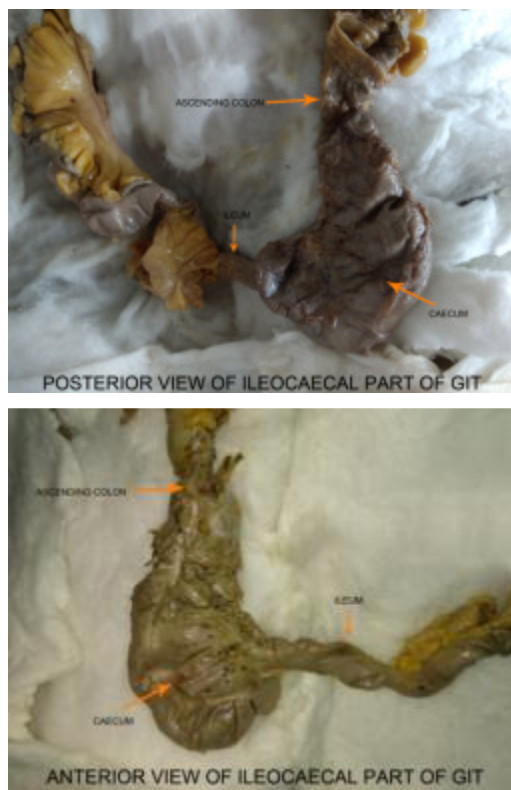
In the present study we reported the uncommon absence of the appendix. This variation is important during surgeries related to colon.

Case Report

Using conventional dissecting techniques, the anterior abdominal wall was dissected in a approximately 47-year-old embalmed male cadaver, with a purpose of preparation of the museum anatomical specimens and teaching. The medical history of this cadaver was not available. In the present case we reported a very rare case of agenesis of appendix vermiformis. Which normally present on posteromedial side of caecum in right iliac fossa. Following the dissection, the agenesis of appendix was photographed.

In the present case, we noticed that the ileum meets with the caecum on its medial side in the right iliac fossa and forms the ileocaecal junction. Caecum is a large blind sac forming the commencement of the large intestine. Caecum communicates superiorly with the ascending colon, medially at the level of caecocolic junction with the ileum, and posteromedially with the appendix.

(Figure 1).



Discussion-

Vermiform Appendix develops from lower narrower part of caecal diverticulum, which arises from distal limb of midgut loop. Then it reaches the right iliac fossa, the caecum and appendix undergo a 270° rotation around the superior mesenteric artery. The mesentery of appendix is known as mesoappendix, which gives passage to appendicular artery. If appendix does not develop then, there would be obvious absence of appendicular artery. There is a congenital disease known as jejuna atresia or short gut syndrome in which appendix may be absent. It has been proved in researches that Thalidomide causes agenesis of appendix.

Conclusion

The vermiform appendix is a derivative of the end of the primitive herbivorous caecum which was found in our primate ancestors. The appendix has no role in cellulose digestion. Since, lymphoid aggregations are found in appendix, it can be concluded that it has some role in maintaining gastrointestinal immunity. Also, intestines are provided with Peyer's patches. Thus, vermiform appendix is not further required hence, it is a vestigial organ. Soon, in the evolution, a day will come when appendix would be absent in the human body. Then, we can imagine that on that day, we would be escaped from the disadvantages of the appendix.

References

1. Nissler V, Fleischmann J, Hummer HP, Knorr C. Agenesis of the vermiform appendix. *J Pediatr Surg.* 2012;47:1302–1303. doi: 10.1016/j.jpedsurg.2012.03.050.
2. Standring S, ed. *Gray's Anatomy. The Anatomical Basis of Clinical Practice.* 40th Ed., Edinburg, Churchill & Livingstone. 2008; 1231, 1233.
3. Hei EL. Congenital absence of the vermiform appendix. *ANZ J Surg.* 2003;73(10):862. doi: 10.1046/j.1445-2197.2003.02807.x.
4. elarue A, Chappuis JP, Esposito C, Valla JS, Bonnevalle M, Allal H, Robert M. Is the appendix graft suitable for routine biliary surgery in children? *J Pediatr Surg.* 2000;35:1312–1316. doi: 10.1053/jpsu.2000.9313.
5. Chèvre F, Gillet M, Vuilleumier H. Agenesis of the vermiform appendix. *Surg Laparosc Endosc Percutan Tech* 2000; 10:110-2.
6. Woywodt A, Verhaart S, Kiss A. Atresia of the appendix. *J Pediatr Surg* 1998; 33:1423-5.
7. Seashore JH, Collins FS, Markowitz RI, Seashore MR. Familial apple peel jejunal atresia: surgical, genetic and radiological aspects. *Pediatrics* 1987; 80:540-4.
8. Slavin JL, Brauer PM, Marlett JA. Neutral detergent fiber, hemicelluloses and cellulose digestibility in human subjects. *J Nutr* 1981; 111:287-97.
9. Bremner DN, Mooney G. Agenesis of appendix: a further thalidomide anomaly. *Lancet.* 1978;1:826. doi: 10.1016/S0140-6736(78)93029-5.
10. Shand JE, Bremner DN. Agenesis of the vermiform appendix in a thalidomide child. *Br J Surg* 1977; 64:203-4.